

Up-to Date Review And Case Report

Are zygomatic implants a simple and reliable technique for the stabilization of obturator prostheses? Case report and review of the literature

Benjamin Sender^{1,2,*}, Thibault Lacroix¹, Philippe Jaby², Anne-Gaelle Chaux-Bodard^{1,3}

¹ Oral surgery, centre de consultations et de soins dentaires, 6 place Depéret, Lyon 69007, France

² Maxillo-facial Department, Hôpital de la Croix Rousse, 103 grande rue de la croix rousse, Lyon 69004, France

³ Oncological surgery Department, Centre Léon Bérard 28 rue Laennec, Lyon 69008, France

(Received: 12 July 2019, accepted: 12 January 2020)

Keywords:
maxillectomy /
zygomatic implants /
obturator prosthesis

Abstract – Zygomatic implants have been used for several years for the treatment of extremely resorbed maxilla. Indications were extended for oral rehabilitations after maxillectomy in oncologic patients. A 24-year old patient with a triple A syndrome who underwent a left maxillectomy due to a spinocellular tumour was addressed for prosthetic rehabilitation. As his obturator prosthesis failed, surgical closure of the defect combined with 2 zygomatic implants to support the prosthesis was proposed. Despite a small persistent oro-antral fistula, the new obturator prosthesis restored the patient's functions and esthetics and improved his quality of life. The literature reports less than 40 cases of maxillectomy patients rehabilitated with zygomatic implants (with or without flap closure of the defect). Regardless of implant placement, there is no significant difference between reconstructive surgery and obturator prosthesis. Thus, zygomatic implants seem to be a reliable method for the stabilization of obturator prosthesis, without complex surgical procedure. Nonetheless, reservations should be expressed given the lack of data in terms of long-term follow up.

Introduction

Zygomatic implants (ZI) have been used for several years as part of the prosthodontic rehabilitation in patients with maxillary atrophy. The technique was introduced in 1998 by Branemark to provide retention and stability for conventional removable dentures and has progressed to reconcile prosthodontic goals with anatomic reality. These specific implants allow an anchorage distally from the maxilla and the literature shows a success rate similar to conventional osseointegrated implants [1,2].

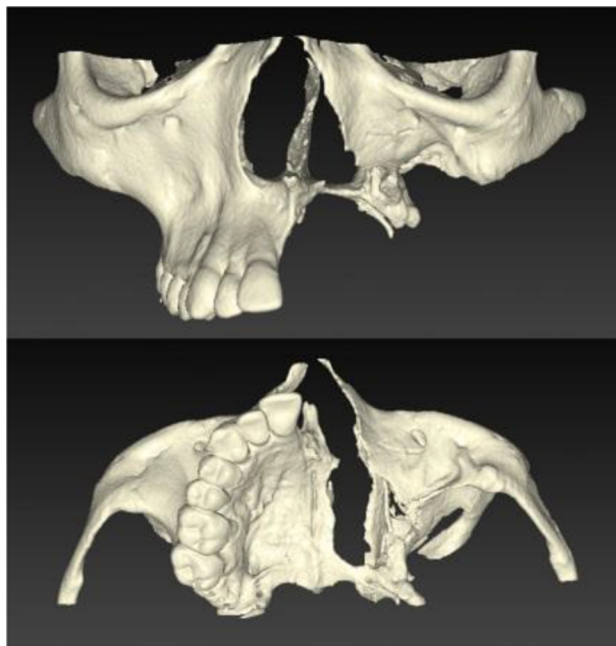Their indications were thus extended for the rehabilitation of maxillectomy using zygomatic implant to stabilize obturator prosthesis is well described in the literature [3–6]. This article aims to report the case of a young, physically challenged hemimaxillectomy patient treated with zygomatic implants and obturator prosthesis and review the available data.

Observation

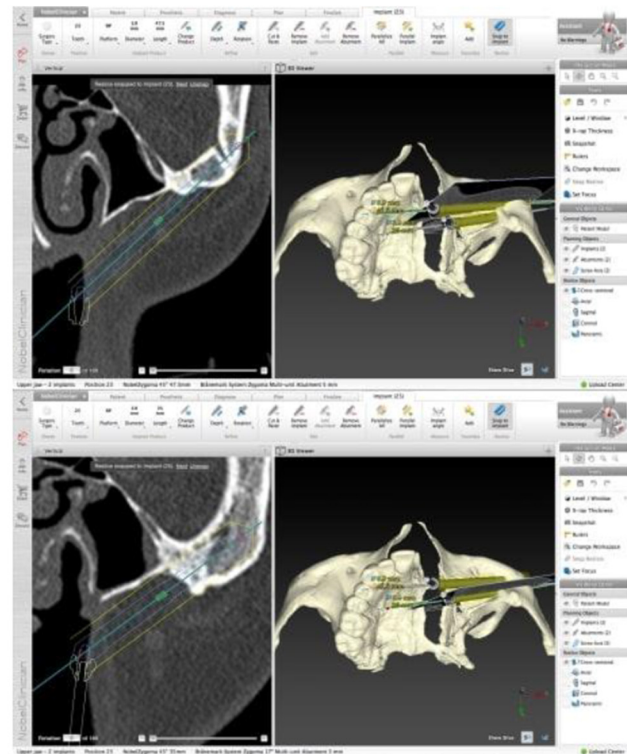A 24 year-old male patient suffering from a triple A syndrome was referred to the oral and maxillofacial surgery

department to close an oroantral fistula and propose a prosthetic rehabilitation of the missing teeth. The patient also presented with dysphagia caused by achalasia (treated by 2 esophageal dilatations in 2008 and 2011), a motor and sensory neuropathy of the upper limb, an adrenal insufficiency (substituted by hydrocortisone since he was 4 years old) and alacrima. Because of his neuropathy, the patient had problems in everyday routine tasks, especially as he underwent a vertebral arthrodesis related to a severe scoliosis in 2010. A low grade squamous cell carcinoma was removed from the left maxilla in 2008; no adjuvant therapy was proposed. Surgery resulted in a left maxillary defect type IIb of the Brown's classification and an oroantral communication. The patient was rapidly rehabilitated with conventional obturator prosthesis during 8 years but the instability of his prosthesis led the patient to consider other options. A free flap to close the defect was proposed but the patient declined. An alternative solution was proposed, as a closure of the defect with a rotation flap and placement of zygomatic implants. Surgery was performed under general anaesthesia, after a surgical planning using the NobelClinician® software. After bone exposition, we use a surgical stent to place two zygomatic implants using extra sinusal technique. We used 45° angulated implant with a diameter of 3.9 mm and 47.5/35 mm length (in position of

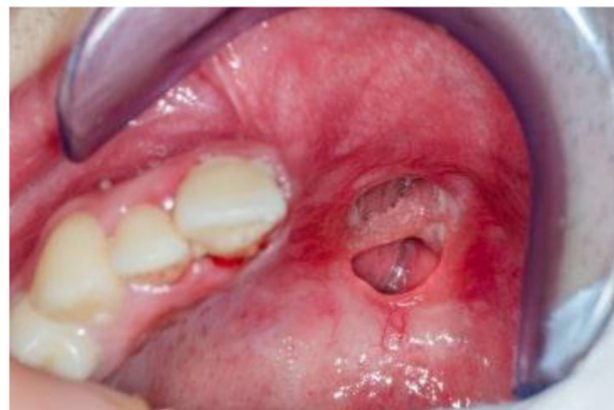* Correspondence: benjaminsender13@gmail.com



(a)



(b)



(c)

Fig. 1. Pre operative situation. (a) Maxillary defect, (b) implant planification (Nobelclinician® software), (c) intrabuccal view of the fistula.

tooth no. 23 and tooth no. 25, respectively) (Fig. 1). The buccal fat pad was used to isolate the implants from the oral and nasal cavities and to prevent from the dehiscence of peri implant soft tissues, which could cause implant exposure and reduce their longevity.

Per- and postoperative medication consisted of antibiotics (amoxicillin 1g + clavulanic acid 125 mg started the morning of the surgery day), 3 times per day, during 10 days and analgesics (tramadol 50 mg). Postoperative recovery was uneventful.

After the completion of the 3 months healing period, the clinical stability and osseointegration of the implants was good but a persistent small oroantral fistula was observed (Fig. 2). As

the patient presented with a good contralateral toothings despite a slight misalignment and a poor oral hygiene, the rehabilitation consisted in a bar-retained obturator prosthesis (Fig. 3). A secondary closure of the remaining fistula was proposed but the patient refused, as he was satisfied with his obturator prosthesis which he wore 12 to 18 hours per day. The patient's satisfaction was good in terms of function and esthetics and he reported a major improvement of his chewing ability (Fig. 4).

Clinical and radiological controls were performed every 3 months during one year and then twice a year. Global follow up was 2 years.

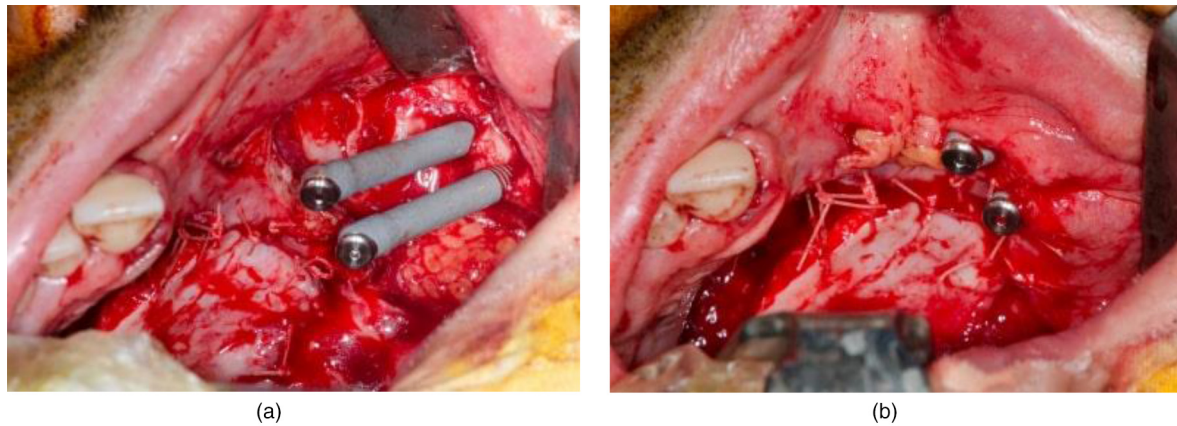


Fig. 2. Surgical phase. (a) Intrabuccal view of the fistula (b) flap closure with buccal fat pad.

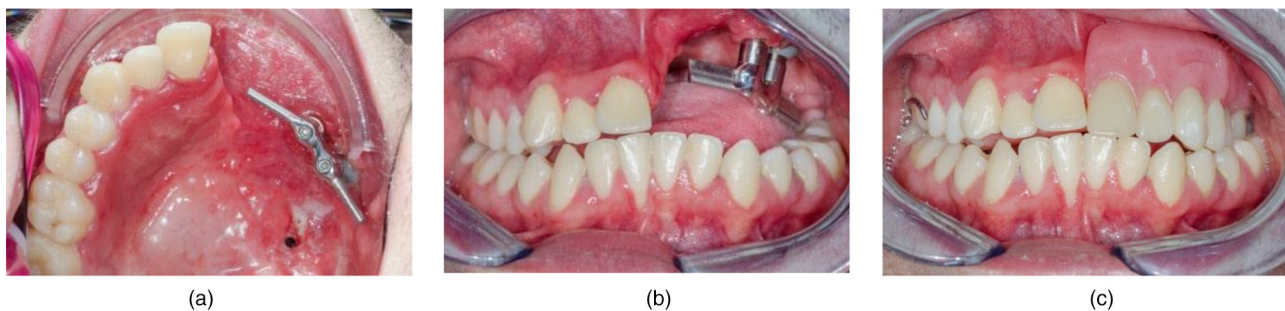


Fig. 3. Prosthesis. (a) Transversal view of retention bar, (b) frontal view of retention bar, (c) intraoral view with prosthesis.

Commentary

The patient suffered from a triple A syndrome, an autosomal multisystemic disease, which render complete overview of the patient's abilities mandatory before choosing a therapeutic solution.

Surgical steps for ZI placement are quite different from conventional implant placement, especially in case of maxillectomy patients, as the only anchorage is in the zygoma and thus results in a long lever arm. Thus, surgical planning is mandatory as no anatomical mark persists (no remaining maxilla alveolar crest). The zygoma has to be surgically exposed. The drilling sequence consists of a round bur, and 2.9 mm, 3.5 mm and a final drill of 3.5 mm of diameter. The implants are then placed, following the planning. A fat pad is preferable to prevent the contact between the implants and nasal mucosa or oral cavity, avoiding the risk of implant exposure and loss due to the dehiscence of peri implant soft tissues. Implant loading could be immediate or delayed according to the primary stability of the implants. Because of the lack of information regarding the loading of zygoma implant stabilized prosthesis we chose the second solution.

The ideal emergence of ZI is on the lateral incisor for the mesial ZI and the second premolar for the distal ZI. This placement allows a better repartition of occlusal stress, but is

not always possible in case of maxillectomy patients; in this case, anatomical constraints did not allow this placement and the mesial implant had to be placed more posterior.

Initial goal of the surgery was to close the oronasal communication but the flap didn't allow it completely. The closure of the communication, using a vascularized free flap and implant supported prosthesis was proposed secondarily to the patient but he refused this complex surgery in which serious complications or rehabilitation failure may occur [7–10]. He was very satisfied with his ZI stabilized obturator whose aesthetic aspect was considered as very satisfactory and that has considerably improved his chewing ability as shown by the quality of life questionnaire based on the publication of El Sayed (Fig. 4) [11]. Although some studies show that closure of the oronasal communication using free flap are preferable to implant stabilized obturators in case of large defects [9], there are no significant differences in case of mid size defects, regarding psychological effects [12] and speech intelligibility [9,12–14]. If maxillary reconstructions show generally best results for improving chewing performance [15,16], remaining teeth on contralateral maxilla improve obturator performances [17]. There are no differences regarding swallowing functions [9,16] and the literature show contradictory results concerning aesthetics results: while there are no significant differences in some case [13], other authors report a highest level of

- Q1: during the day, how many hours do you wear your obturator prosthesis?
- ☐ nearly 24h
 - ☒ nearly 12h (between 12 and 18 hours)
 - ☐ less than 8h
 - ☐ nearly not worn
- Q2 : do you wear your obturator prosthesis for social occasions?
- ☒ yes
 - ☐ No
- Q3 : do you wear your obturator for eating?
- ☒ yes
 - ☐ No
- Q4 : how well are you able to chew your daily soft food?
- ☒ no difficulty
 - ☐ little difficulty
 - ☐ great difficulty
- Q5 : can you eat hard food?
- ☒ yes
 - ☐ No
- Q6 : can you eat on the defect side comfortably?
- ☒ yes (as often is possible)
 - ☐ No
- Q7 : how well are you able to swallow daily food?
- ☒ no difficulty
 - ☐ little difficulty
 - ☐ great difficulty
- Q8 : how well is the oro-nasal separation during drinking and eating?
- ☐ very good
 - ☒ fairly good
 - ☐ fairly bad
 - ☐ very bad
- Q9 : can you speak comfortably with your obturator prosthesis without dislodgement?
- ☒ yes, for long period of time
 - ☐ yes, for short period of time
 - ☐ no, i can't speak with it
- Q10 : in your opinion, how stable is your obturator during speech?
- ☒ very good
 - ☐ fairly good
 - ☐ fairly bad
 - ☐ very bad
- Q11 : how satisfied are you with your obturator prosthesis esthetics?
- ☒ very satisfied
 - ☐ fairly satisfied
 - ☐ fairly unsatisfied
 - ☐ very unsatisfied
- Q12 : do you perform oral hygiene care?
- ☐ Regularly
 - ☒ not often
 - ☐ not at all
- Q13 : how much is the effect of your obturator prosthesis on your daily life?
- ☒ great effect
 - ☐ moderate effect
 - ☐ minor effect
 - ☐ no effect
- Q14 : by the help of your obturator prosthesis, do you feel that you are :
- ☐ normal person
 - ☒ near normal
 - ☐ abnormal

Fig. 4. Quality of life questionnaire based on El Sayed publication [11].

dissatisfaction in patients treated with obturator even though they cannot explain it clearly [12,14,18]. Moreover, the maintenance of a removable denture is easier, which was mandatory in this case.

The main question remains the type of implant-prosthesis connexion. Low force magnetic attachments have been described [5], or bars [3,6]. Despite a lack of consensus, the authors seem to recommend securing the implants to ensure the durability of the rehabilitation. Additionally, connecting the implants provides a better sustain: a bar with mesial and distal extensions was made to better distribute occlusal forces and improve the retention and stability. Actually, overloading of zygomatic implants could be one of the causes of implant loss [3,6]. At last, it seems that in case of hemimaxillectomy in edentulous patients, ZI allow a better transmission of occlusal stress than conventional implants in the non-operative side [19,20].

Conclusion

The rehabilitation strategy for maxillectomy patients is controversial. The surgeon must deal with postsurgical oncologic anatomy and the patient's need. Maxillary obturator stabilized by zygomatic implants is an interesting alternative to maxillary reconstructions with implant supported or implant stabilized prosthesis. This will be particularly true in patients with poor status, guarded prognosis or who are unable to easily clean up their prosthesis. This treatment allows a high level of comfort and improvement of the quality of life.

Conflicts of interests: The authors declare that they have no conflicts of interest in relation to this article.

References

1. Aparicio C, Manresa C, Francisco K, Claros P, Alánde J, González-Martín O, *et al.* Zygomatic implants: indications, techniques and outcomes, and the zygomatic success code. *Periodontol* 2000 2014;66:41–58.
2. Chrcanovic BR, Albrektsson T, Wennerberg A. Survival and complications of zygomatic implants: an updated systematic review. *J Oral Maxillofac Surg* 2016;74:1949–1964.
3. Dattani A, Richardson D, Butterworth CJ. A novel report on the use of an oncology zygomatic implant-retained maxillary obturator in a paediatric patient. *Int J Implant Dent* 2017;3:9.
4. Pellegrino G, Tarsitano A, Basile F, Pizzigallo A, Marchetti C. Computer-aided rehabilitation of maxillary oncological defects using zygomatic implants: a defect-based classification. *J Oral Maxillofac Surg* 2015;73:2446.e1–2446.e11.
5. Ozaki H, Ishikawa S, Kitabatake K, Yusa K, Sakurai H, Iino M. Functional and aesthetic rehabilitation with maxillary prosthesis supported by two zygomatic implants for maxillary defect resulting from cancer ablative surgery: a case report/technique article. *Odontology* 2016;104:233–238.
6. Atalay B, Doganay Ö, Saraçoğlu BK, Bultan Ö, Hafiz G. Clinical evaluation of zygomatic implant-supported fixed and removable prosthesis. *J Craniofac Surg* 2017;28:185–189.
7. Bernhart BJ, Huryn JM, Disa J, Shah JP, Zlotolow IM. Hard palate resection, microvascular reconstruction, and prosthetic restoration: a 14-year retrospective analysis. *Head Neck* 2003;25:671–680.
8. Baliarsing AS, Kumar VV, Malik NA, B DK. Reconstruction of maxillectomy defects using deep circumflex iliac artery-based composite free flap. *Oral Surg Oral Med Oral Pathol Oral Radiol Endod* 2010;109:e8–13.
9. Moreno MA, Skoracki RJ, Hanna EY, Hanasono MM. Microvascular free flap reconstruction versus palatal obturation for maxillectomy defects. *Head Neck* 2010;32:860–868.
10. Costa H, Zenha H, Sequeira H, Coelho G, Gomes N, Pinto C, *et al.* Microsurgical reconstruction of the maxilla: Algorithm and concepts. *J Plast Reconstr Aesthet Surg* 2015;68:e89–104.
11. El-Sayed WM, Gad MA, Medra AM. Prosthodontic management of maxillectomy patients with dental implants in residual zygomatic bone: a preliminary report. *Int J Prosthodont.* 2014;27:534–540.
12. Rogers SN, Lowe D, McNally D, Brown JS, Vaughan ED. Health-related quality of life after maxillectomy: a comparison between prosthetic obturation and free flap. *J Oral Maxillofac Surg* 2003;61:174–181.
13. Rieger JM, Tang JAL, Wolfaardt J, Harris J, Seikaly H. Comparison of speech and aesthetic outcomes in patients with maxillary reconstruction versus maxillary obturators after maxillectomy. *J Otolaryngol Head Neck Surg* 2011;40:40–47.
14. Wang F, Huang W, Zhang C, Sun J, Qu X, Wu Y. Functional outcome and quality of life after a maxillectomy: a comparison between an implant supported obturator and implant supported fixed prostheses in a free vascularized flap. *Clin Oral Implants Res* 2017;28:137–143.
15. Genden EM, Okay D, Stepp MT, Rezaee RP, Mojica JS, Buchbinder D, *et al.* Comparison of functional and quality-of-life outcomes in patients with and without palatomaxillary reconstruction: a preliminary report. *Arch Otolaryngol Head Neck Surg.* 2003;129:775–780.
16. Sreeraj R, Krishnan V, V M, Thankappan K. Comparison of masticatory and swallowing functional outcomes in surgically and prosthetically rehabilitated maxillectomy patients. *Int J Prosthodont* 2017;30:573–576.
17. Vero N, Mishra N, Singh BP, Singh K, Jurel SK, Kumar V. Assessment of swallowing and masticatory performance in obturator wearers: a clinical study. *J Adv Prosthodont* 2015;7:8–14.
18. Breeze J, Rennie A, Morrison A, Dawson D, Tipper J, Rehman K, *et al.* Health-related quality of life after maxillectomy: obturator rehabilitation compared with flap reconstruction. *Br J Oral Maxillofac Surg* 2016;54:857–862.
19. Korkmaz FM, Korkmaz YT, Yalug S, Korkmaz T. Impact of dental and zygomatic implants on stress distribution in maxillary defects: a 3-dimensional finite element analysis study. *J Oral Implantol* 2012;38:557–567.
20. Akay C, Yalug S. Biomechanical 3-dimensional finite element analysis of obturator prostheses retained with zygomatic and dental implants in maxillary defects. *Med Sci Monit.* 2015;21:604–611.